EXAM COMMITTEE

15th Batch NEU-241 Final

Disclaimer: Despite our best efforts, we cannot guarantee the absolute accuracy of our answers. For complete certainty, please refer back to the lectures. We sincerely apologize for any mistakes.

Do not share the document with the doctors!

OSPE:

17/20

Q1)

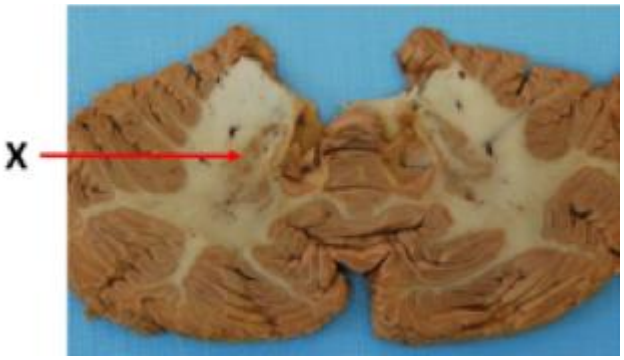

1. Name one connection of the nucleus marked as X
2. Give the function of this nucleus.

Ans:

1. Primary Motor Cortex
2. Correction of Intended plan of action

Q2) A middle-aged woman presented with series of dizzy spells for past six months accompanied by tinnitus in her right ear.

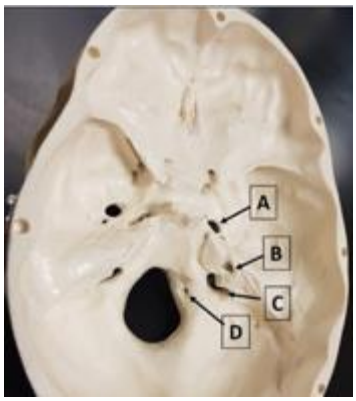

1. Which of the marked foramen A, B, C and D allows the cranial nerve that is affected in this case? (See the attached image)

2. Which other cranial nerve pass through this same foramen?

Ans:

1. B
2. CN7 (Facial)

Q3) An EMG study is done on a diabetic patient for peripheral neuropathy. The result shown in the graph attached the stimulus in RED, and the response of the thenar muscle in BLUE. The time is 4 msec and the distance 20 cm.

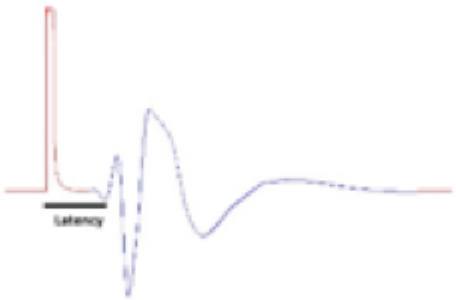

1. Calculate the conduction velocity of the median nerve in meters per second (m/sec).

2. Suggest a reason for the latency shown in the result.

Ans:

1. 50 m/sec
2. Peripheral Nerve Damage

Q4)

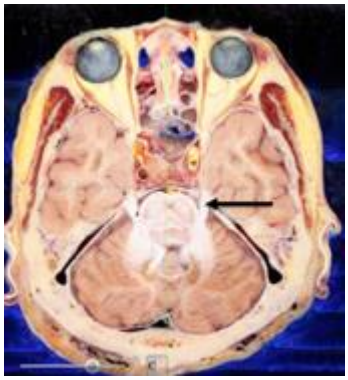

1. Name the structure marked with black arrow.
2. List one clinical manifestation that may result from damage to the marked structure.

Ans:

1. Trigeminal (CN5)
2. Loss of Pain and temperature sensation on Face

Q5) A photomicrograph of a patient's CSF is shown in the attached image. What would the CSF analysis show (mention TWO distinguishing parameters)?

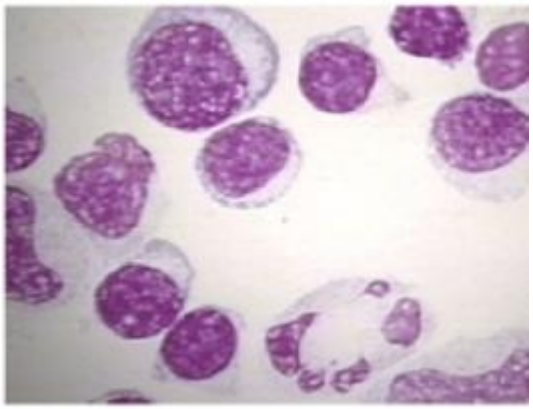

Ans:

1. Elevated Protein
2. Normal Glucose
3. Lymphocytes

Q6) Identify the marked structure 1,2,3,4.

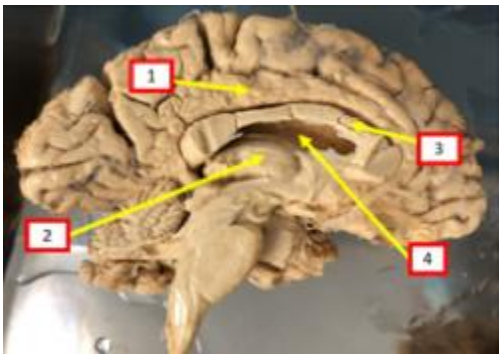

Ans:

1. Cingulate Gyrus
2. Thalamus
3. Corpus colosum
4. Lateral Ventricle

Q7) Name the structure 1,2,3,4.

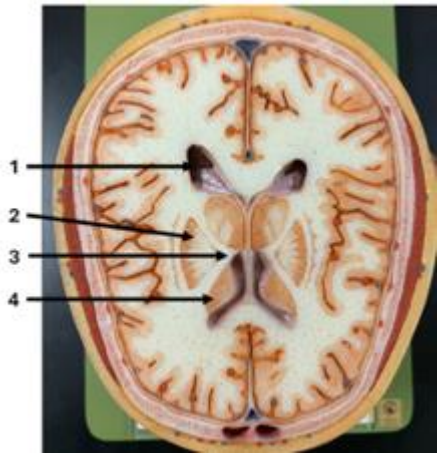

Ans:

1. Lateral Ventricles (Posterior Horn)
2. Lentiform Nucleus
3. Genu of Internal Capsule
4. Caudate Nucleus

Q8)

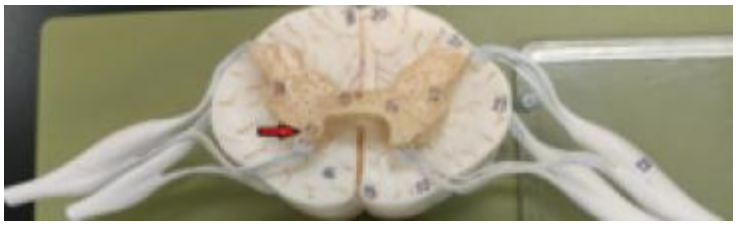

1- Name the structure marked with the red arrow

2- Name one clinical condition involves it

Ans:

1. Anterior Horn
2. Amyotrophic Lateral Sclerosis (ALS)

Q9) The shown phenomena is observed between which pairs of microorganisms involved in CNS infection?



Ans: S.aureus and H.influenzae

Q10) Name the structures 1,2,3,4.

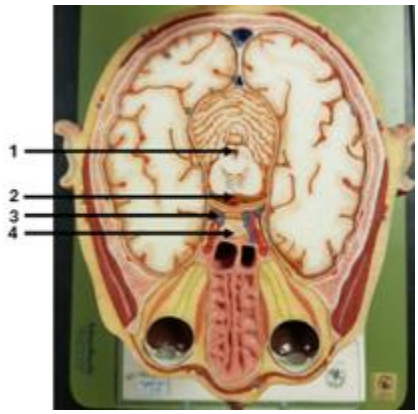

Ans:

1. Central Canal
2. Basilar Artery
3. Internal Carotid
4. Optic Chiasm

Q11)

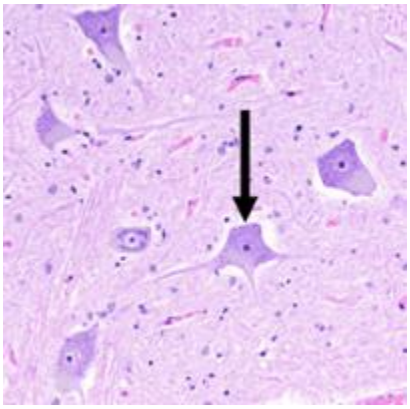

1- Name the marked cell.

2- List two any location where the marked cell is found.

Ans:

1. Multipolar Neurons
2. Anterior Horn of Spinal Cord and Purkinje cell (In cerebellum)

Q12)

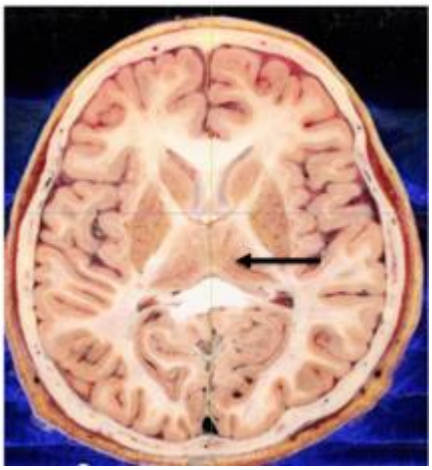

1- Name the marked structure.

2- Name 2 sources that supply the marked structure.

Ans:

1. Thalamus
2. Artery of Percheron and Posterior Cerebellar Artery

Q13) A 55-year-old female was brought to the ER with decrease salivation and sagging of left angle of mouth.

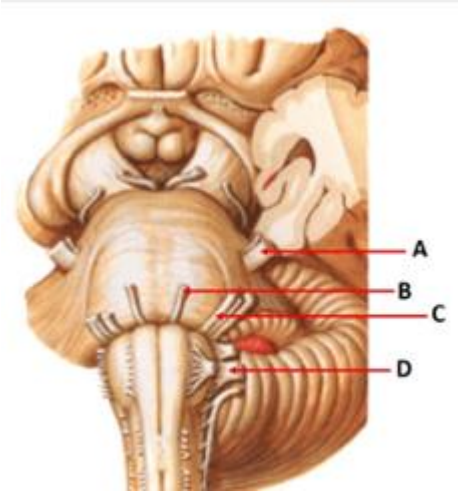

1- which one of the labelled nerves A,B,C,D is involved in this case? (see the attached image)
2- Name the nuclei involved in this case.

Ans:

1. C (Facial Nerve)
2. Superior Salivatory Nucleus

Q14)

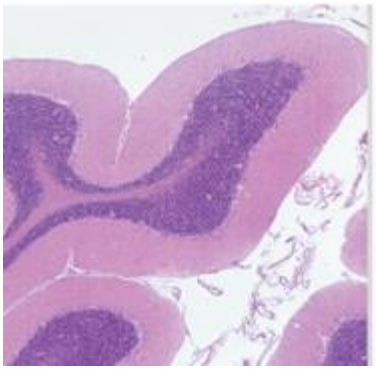

1- Name the structure shown in the attached photomicrograph.

2- Name the cell which makes the major output from the shown structure.

Ans:

1. Cerebellum
2. Purkinje Cell

Q15)

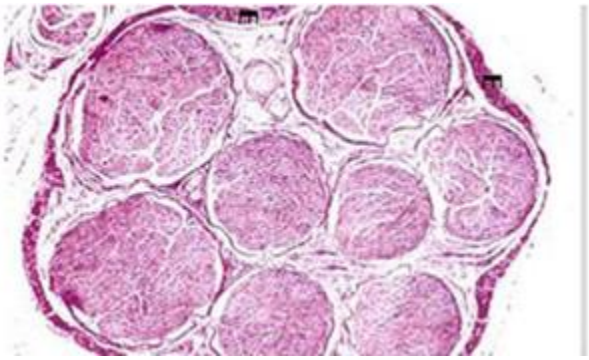

1- Name the structure

2- Two points of identification

Ans:

1. Peripheral Nerve

2. Epineurium surrounding nerve and Perineurium surrounding Nerve Fascicles

Q16)

1- Name the structure encircled in red.

2- What are the neurological manifestation results due to a stroke to that area?

Ans:

1. Wernicke's Area
2. Wernicke's Aphasia/Receptive Aphasia

Q17) A medical student recorded the EEG (attached in the picture) in a relaxed, calm, and quiet laboratory settings while he was awake with his eyes closed. He was asked to open his eyes, what change would be expected in the EEG wave tracing?

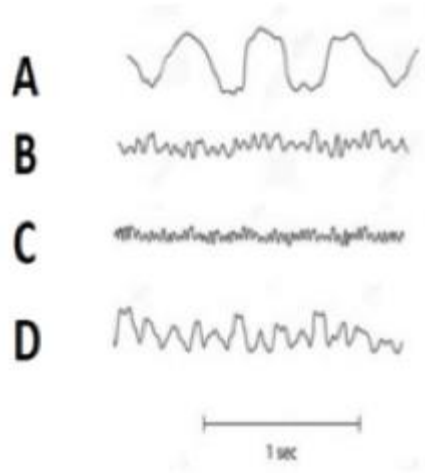

Ans:

From C (Alpha) to B (Beta)

Q18) Question about Lateral Medullary Syndrome, Point at the artery affected

SAQ:

10/10 questions

Case 1

Roy is a 65-year-old smoker with high blood pressure and irregular heartbeat (atrial fibrillation). He collapsed due to a severe headache. His father died young due to a heart attack. Roy's level of consciousness was graded on the Glasgow Coma Score. He did not respond to verbal commands. On strong painful stimuli, he only opened his eyes and had abnormal flexion of his arms. His blood pressure is high, his heartbeat is irregular, and he has optic disc edema and right facial droop. However, his forehead appeared normal, and his reflexes were symmetrical. ECG confirmed atrial fibrillation. Lab investigations showed an INR of 6.1. A non-contrast CT scan of his head is attached.

Q1) Calculate the Glasgow coma score in this patient?

Ans:

Verbal: 1

Eye: 2

Body Movement: 3

Total: 6

Q2) Why did this patient collapse and become unconscious?

Ans:

Loss of Blood supply to the brain= Loss of Oxygen= Unconsciousness

Q3) What is the significance of INR in this case?

Ans:

Important for Spinal Tap/Lumbar Puncture

Q4) List 2 radiological findings of the attached CT scan of the patient

Ans:

1. Hyperdense region
2. Ventricular Compression

Q5) What is the significance of

- Optic Edema
- Lower Face Paralysis
- Symmetrical reflexes in this case

Ans:

Optic Edema: Fluid Buildup in brain (Brain edema)

Lower Face Paralysis: UMN of Facial

Symmetrical Reflexes: We're not sure

Case 2

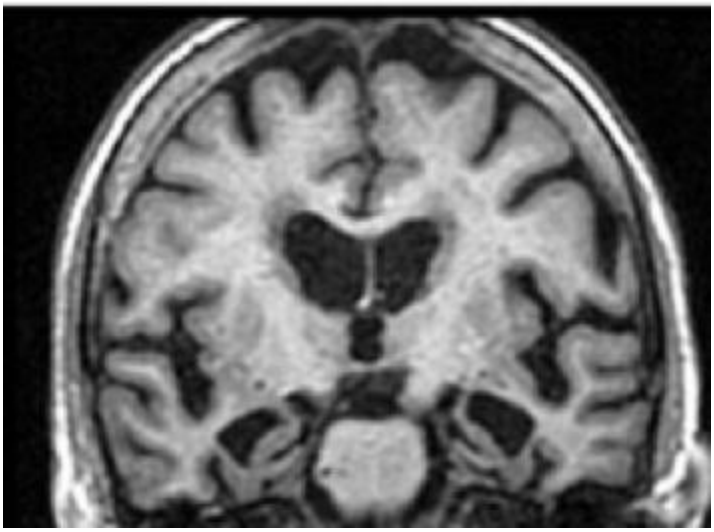

Ahmed, 80, visited the neurology clinic due to memory concerns from his son. He has significant short-term memory loss, neglects personal care, and has unexplained weight loss. His MMSE score dropped from 21 to 19 . Ahmed missed medications and follow-ups and doesn't take prescribed donepezil.

Q1) Which condition is this patient suffering from?

Ans:

Alzheimer’s

Q2) What is MMSE used for?

Ans:

This Exam is used to test for Mental function and Memory

Q3) What are the MRI findings in this case?

Ans:

Widened Sulci, Narrow Gyri, and Ventriculomegaly

Q4) What are the characteristics pathologic findings of the disease affecting this patient

Ans:

Forgetfulness and Loss of way

Q5) What is the MOA of donepezil

Ans:

AChE Inhibitor

MCQ:

104/104

Q1) A patient has an ischemic infarct affecting the anterior spinal artery in the brainstem region. Which one of the following structures are affected by this infarction?

A. Medial lemniscus

B. Spinal lemniscus

C. Abducent nerve

D. Trigeminal lemniscus

E. Lateral lemniscus

Ans: A

Q2) A 40-year-old patient came to the neurological clinic with involuntary jerking or writhing movements (chorea). Overactivity of which one of the labelled circuitries (1-4) will result in choreatic movements in this case?

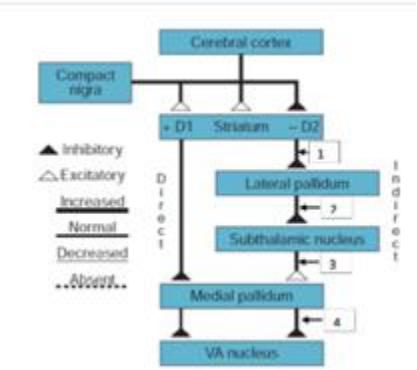

A. 3

B. 2

C. 4

D. 1

Ans: B

Q3) Naltrexone is the treatment of choice for people who are abusing which of the following substance?

A. Cocaine

B. Alprazolam

C. Alcohol

Ans: C

Q4) What is the mechanism of action of this Lorazepam ?

A. An Indirect GABA receptor agonist

B. An Indirect GABA receptor antagonist

C. A mu receptor agonist

D. Increases duration of chloride channel opening

Ans: A

Q5) A 3-year-old boy is evaluated in the ER for fever, malaise, headache, and neck pain. The attending physician suspects viral meningitis. What is the most common cause of viral meningitis in children?

A. Enteroviruses

B. Human Papilloma Viruses

C. Herpes viruses

D. Adenoviruses

E. Mumps

Ans: A

Q6) A 7-year-old presents with 8 days of fever and lethargy. He is febrile, tachycardic, mildly tachypneic, and has neck stiffness. CSF analysis shows low glucose, high protein, and lymphocytic pleocytosis. The Gram smear is negative, and a pellicle forms on standing. What is the infectious agent?

A. Neisseria meningitidis

B. Mycobacterium tuberculosis

C. Staphylococcus aureus

D. Candida albicans

E. Cryptococcus neoformans

Ans: E

Q7) A 15-year-old previously healthy boy presents with fever, headache, vomiting, and diarrhea. He has recently returned from a trip to one of the West African countries. While on his trip, he

did not take any precautions to prevent mosquito bites. The managing team suspects West Nile encephalitis. Which of the following laboratory tests is most likely to confirm the diagnosis?

A. CSF antibody testing

B. Magnetic Resonance Imaging of the head

C. CSF microscopy

D. Computed Tomography of the head

E. Serum ELISA

Ans: E

Q8) A 45-year-old man with a history of relapsing-remitting multiple sclerosis (MS) has been experiencing progressive worsening of his walking ability over the past year. MRI reveals new lesions in the spinal cord. Which type of MS is he suffering from?

A. Clinically isolated syndrome

B. Benign MS

C. Secondary progressive MS

D. Primary progressive MS

E. Relapsing-remitting MS

Ans: C

Q9) An 80-year-old female patient with Parkinson's disease is experiencing bradykinesia and rigidity. Which of the following medications can be used as a direct dopamine receptor agonist to improve motor symptoms?

A. Pramipexole

B. Benztropine

C. Entacapone

Ans: A

Q10) What characteristics do the circumventricular organs (CVOs) share that distinguish them from the rest of the brain?

A. They contain high-density myelin sheets

B. They are not protected by the blood-brain barrier

C. They have a thicker and stronger blood-brain barrier

D. They are devoid of any neuronal tissue

Ans: B

Q11) A 70-year-old patient came to the neurology clinic after a stroke with involuntary violent wide amplitude movements involving right upper and lower limbs. Which one of the following areas are involved in this stroke?

A. Right cerebellar hemisphere

B. Left subthalamus

C. Striatum

D. Posterior limb of internal capsule

E. Right crus cerebri

Ans: B

Q12) A 70-year-old man, 4 weeks post-ischemic stroke with a history of hypertension and type 2 diabetes, presents with unilateral neglect. He only shaves the right side of his face, raises his right arm when asked to lift his left, and places numbers only on the right side of a clock. Which brain area is most likely affected by the stroke?

A. Left temporal cortex

B. Left parietal cortex

C. Left frontal cortex

D. Right parietal cortex

E. Right occipital cortex

Ans: B

Q13) For the past 3 years, a college student has suffered from fatigue, chronic headaches, dizziness, shortness of breath, ringing ears, and constipation. His primary physician recommends a psychiatric evaluation because no organic cause for his symptoms could be found. Which one of the following is the most likely diagnosis?

A. Illness anxiety disorder

B. Obsessive-compulsive disorder

C. Panic disorder

D. Somatic symptom disorder

E. Body dysmorphic disorder

Ans: D

Q14) A woman has a long history of depressive symptoms accompanied by body aches and pain secondary to a car accident 2 years earlier. Physical examination and laboratory tests are unremarkable. Which of the following drugs will be most helpful for this patient's condition?

A. Fluoxetine

B. Phenelzine

C. Sertraline

D. Amitriptyline

Ans: D

Q15) An obsessive male complains of chronic symptoms of snoring, headaches, fatigue, poor sleep, chronic congestion, and irritability. Which one of the following is the most likely disorder?

A. Narcolepsy

B. Sleep paralysis

C. Obstructive sleep apnea

Ans: C

Q16) A long case about a female heroin addict who was given naloxone for her treatment. How did naloxone treat her condition?

A. Competitive inhibition of NMDA-gated calcium channels

B. Irreversible inhibition of calcium channels on pre-synaptic neuron terminal

C. Competitive agonism of heroin at delta opioid receptors

D. Competitive inhibition of heroin at mu opioid receptors

Ans: D

Q17) Which of the following spinal cord segment could be affected if there is a fracture in T1 vertebrae?

A. T2

B. T4

C. T6

D. T3

E. T5

Ans: D

Q18) Migraine headaches are commonly associated with which one of the following pathophysiological mechanisms?

A. Activation of trigeminal nerve pathways

B. Vasospasm of cerebral arteries

C. Impairment of the blood-brain barrier

D. Increased production of cerebrospinal fluid

E. Decreased levels of serotonin in the brain

Ans: A

Q19) A 35-year-old female patient with treatment-resistant schizophrenia is being considered for clozapine therapy. Which of the following laboratory tests is required before initiating clozapine?

A. Liver function tests

B. Renal function tests

C. Complete blood count

D. Electrolyte panel

Ans: C

Q20)

A 5-year-old girl is found on the bathroom floor with an open bottle of a medication labeled "Flurazepam". In the ER, the girl seems somnolent and is weekly responding to stimuli. Which of the following medications is used as an antidote to treat this patient's condition?

A. Triazolam

B. Thiopental

C. Phenobarbital

D. Flumazenil

E. Flurazepam

Ans: D

Q21) A patient presents to the neurology clinic with stroke, Neurological examination few days later showed paralysis of the lower half of the left side of face with sparing of forehead. examination further showed spastic paralysis of the left half of the body and loss of all sensations on the left side. Which one of the following structures is involved in this stroke?

A. Left pyramid of medulla

B. Left internal capsule

C. Right pyramid of medulla

D. Left facial nucleus of pons

E. Right internal capsule

Ans: E

Q22) An old man presents with the complaint of difficulty seeing. The history reveals that the man has hypertension and is mainly noncompliant regarding his medications. The examination reveals that he has visual field defect indicated black on the given image. Which of the following thalamic/metathalamic nuclei has a lesion?

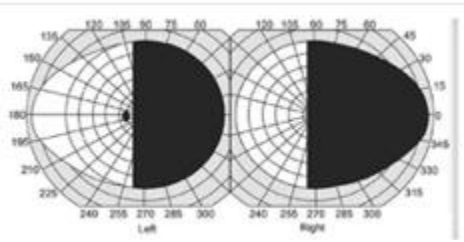

A. Lateral dorsal

B. Lateral geniculate

C. Reticular

D. Medial geniculate

E. Pulvinar

Ans: B

Q23) A female presented with a severe, throbbing right-sided headache for 30 minutes along with nausea, photophobia, and phonophobia. A few hours after receiving a drug, her headache improved but she complained of chest tightness and heaviness. Which one of the following drugs was given to her?

A. Aspirin

B. Methysergide

C. Paracetamol

D. Sumatriptan

E. Propranolol

Ans: D

Q24) Severe psychomotor retardation and severe slowness are typically seen in patients with which one of the following conditions?

A. Cocaine use

B. Melancholic depression

C. Mixed depression and general anxiety disorder

D. Alcohol withdrawal syndrome

Ans: B

Q25) Which of the following MRI sequences is the cerebrospinal fluid hyperintense?

A. T1 with contrast

B. Diffusion-weighted

C. FLAIR

D. T2

E. T1 without contrast

Ans: D

Q26) Which one of the following statements best describes bulimia nervosa?

A. Can be easily treated with antidepressants like Bupropion

B. Usually have no menstrual cycle for at least 3 months

C. Lack of enjoyment when eating

D. BMI is below 18

E. Usually triggered by environmental stress

Ans: C

Q27) A 35-year-old pregnant female presented with severe unilateral throbbing headache: and nausea for two hours. She had: ringing and vision distortion before headaches, Investigations were unremarkable for any intra-cranial mass, Which of the following drugs should be avoided?

A. Paracetamol

B. Sumatriptan

C. Diclofenac

D. Ergotamine

E. Propranolol

Ans: D

Q28) What is the correct definition of epilepsy?

A. At least 2 provoked seizures occurring more than 24 hours apart

B. Any recurring episodes of fainting and abnormal movements

C. One episode of seizure is enough to label someone as epilepsy

D. At least 2 unprovoked seizures occurring more than 24 hours apart

E. At least 2 unprovoked seizures occurring less than 24 hours apart

Ans: D

Q29) A 70-year-old patient came to the neurological clinic with masked face, stooped gait, pill rolling tremors and difficulty in starting movements (akinesia). Overactivity of which one the labelled neuronal circuits (1-4) is responsible for akinesia in this case?

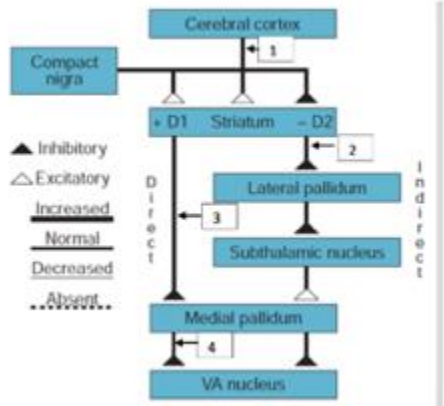

A. 2

B. 4

C. 3

D. 1

Ans: B

Q30) Which one of the following is the most common reason for relapse in schizophrenia?

A. Using ineffective medications

B. Poor compliance with medications

C. Having comorbid physical illness

D. Using alcohol

Ans: B

Q31) A middle-aged man is chronically preoccupied with his health. For many years, he feared that his irregular Bowel functions meant he had cancer. Now he is very worried about having a serious heart disease, despite his physician's assurance that the occasional "extra beats" he detects when he checks his pulse are completely benign. Which one of the following is the most likely diagnosis?

A. Delusional disorder

B. Somatic symptom disorder

C. Illness anxiety disorder

D. Pain disorder

E. Anxiety disorder due to medical illness

Ans: C

Q32) In Huntington's Disease, which brain region demonstrates the most severe atrophy on post-mortem examination?

A. Cerebellum

B. Thalamus

C. Striatum

D. Substantia Nigra

E. Hippocampus

Ans: C

Q33) A patient came to the ER with hemi-section of the left side of spinal cord at T8 spinal segment after a motor vehicle accident. A neurological examination will demonstrate which one of the following clinical signs:

A. Loss of pain the right lower limb
B. Loss of pain in the right upper limb
C. Loss of vibration in right lower limb
D. Loss of vibration the right groin region
E. Loss of pain on the left groin region

Ans: A

Q34) A 54-year-old man is brought to the emergency department by his wife after he develops difficulty speaking. When asked about the onset of his symptoms, the patient slowly responds with "I... weak... morning..." and becomes very frustrated. His wife says that he was able to grasp a pen without any problem while completing medical release forms, but had trouble signing his name. On examination, he is able to state his first name but with difficulty, and correctly points to different body parts on command. This patient's speech difficulties are most likely caused by a lesion affecting which of the following brain areas?

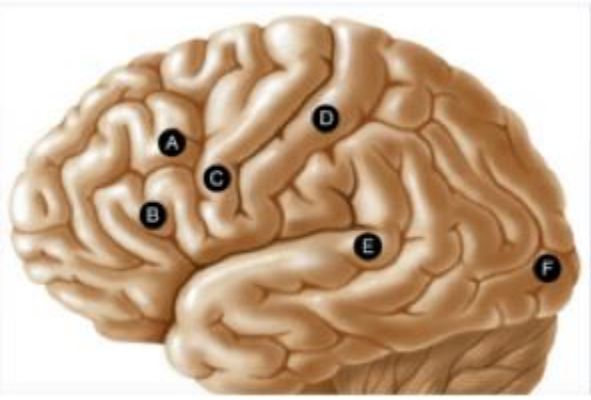

A. C

B. A

C. F

D. B

E. E

F. D

Ans: D

Q35) Fear of public speaking is considered part of which one of the following conditions?

A. Social anxiety disorder
B. Major depression
C. Panic disorder

D. Avoidant personality disorder
E. Bipolar depression

Ans: A

Q36) Which one of the following is a major symptom of generalized anxiety disorder in the DSM 5 criteria?

A Pressured speech

B Impulsivity

C Restlessness and difficulty concentrating

D Depressed mood

E Duration of more than 2 weeks

Ans: C

Q37) A 75-year-old female patient with Parkinson's disease develops psychosis as a side effect of levodopa therapy. Which one of the following medications can be used to manage psychosis without worsening motor symptoms?

A Rotigotine

B Quetiapine

C Entacapone

D Safinamide

Ans: B

Q38) Which one of the following is the best treatment for obsessive-compulsive disorder (OCD)?

A Cognitive behavioral therapy (CBT)

B Selective serotonin reuptake inhibitors (SSRI's)

C Combination of cognitive behavioral therapy and SSRIs

D Benzodiazepines

E Eye movement desensitization

Ans: C

Q39) A 45-year-old man comes to the clinic due to several weeks of difficulty walking and frequent falls. He was previously diagnosed with syphilis. He has a wide-based gait and a positive Romberg sign. Which one of the following structures is involved in this case?

A Thalamus

B Cerebellum

C Lateral spinothalamic tract

D Dorsal column tracts

E Corticospinal tract

Ans: D

Q40) Cocaine increases the bioavailability of which of the following sets of neurotransmitters?

A Norepinephrine/ dopamine/ serotonin

B Glycine/ dopamine/ epinephrine

C Glutamate/ endorphins/ cannabinoids

D Histamine/ norepinephrine/ glycine

Ans: A

Q41) A patient presented to neurology clinic with right sided complete paralysis of the face with deviation of the angle of the face to the left after a viral infection. Which one of the following structures is involved in this case?

A Left facial nerve

B Right hypoglossal nerve

C Upper motor paralysis of right facial nerve

D Right facial nerve

E Right mandibular nerve

Ans: D

Q42) Which one of the following is the most important advice for a bipolar patient and his family?

A Bipolar is an acute illness will be cured with medications

B Should have supervision when managing his money

C Should stay on lithium as it has very few side effect

D Should always be on antidepressants

Ans: B

Q43) Sameera is a 28-year-old female who was referred to a psychiatrist by her primary care physician for inadequate response to treatment of depression. She is overweight with mood swings, accompanied by paranoia. She had excessive money spending and irritable mood, which usually lasts for 2 weeks, followed by 1 month of depressive symptoms. Which one of the following is the most likely diagnosis?

A General anxiety disorder

B Bipolar 1 disorder

C Schizoaffective disorder

D Psychotic depression

E Bipolar 2 disorder

Ans: E

Q44) Which one of the following is seen in narcolepsy?

A Increase in energy during the day

B Sudden decrease in muscle tone

C Increase in the secretion of Hypocretin

D Usually restful sleep at night

Ans: B

Q45) Optic neuritis, a common inflammatory condition affecting the optic nerve, is frequently associated with which one of the following diseases?

A Diabetic retinopathy

B Glaucoma

C Retinitis pigmentosa

D Macular degeneration

E Multiple sclerosis

Ans: E

Q46) Depression is characterized by which one of the following?

A High level of serotonin

B Negative mental state focusing on the past

C High level of dopamine

D Low activities in the limbic system

Ans: B

Q47) A 70-year-old patient came to the neurological clinic with masked face, stooped gait, pill rolling tremors and difficulty in starting movements (akinesia). Degeneration of which one of the following nuclei can result in this condition.

A Substantia Nigra

B Striatum

C Dentate nucleus

D Globus pallidus

E Nucleus Accumbens

Ans: A

Q48) Which of the following brain structures is often implicated in cases of anterograde amnesia due to its critical role in memory consolidation?

A Amygdala

B Prefrontal cortex

C Thalamus

D Hippocampus

E Cerebellum

Ans: D

Q49) A 32-year-old woman with insomnia undergoes an electroencephalogram (EEG) in a sleep disorder clinic. At 3:00 AM, the EEG technician noted that the women's recordings were exhibiting sleep spindles and K-complex. Which stage of sleep was she in at that time?

A N1

B N2

C R

D N3

Ans: B

Q50) In a healthy adult, which sleep stage typically occupies the MOST time during a normal night's sleep cycle?

A R

B N1

C N3

D N2

Ans: D

Q51) A 17-year-old girl, with no previous health issues, presents to the hospital emergency department with two days history of increasing headache, fever and neck stiffness. The CSF Gram stain reveals presence of Gram-negative diplococci. Based on clinical diagnosis and Gram stain findings, which of the following antimicrobial drugs is the most appropriate empiric choice to treat this patient's condition?

A Rifampicin

B Ampicillin

C Ceftriaxone

D Nafcillin

E Vancomycin

Ans: C

Q52) A 70-year-old right-handed woman comes to the emergency department with left-sided visual loss that she noticed on awakening in the morning. Examination of her visual fields shows left homonymous hemianopia with macular sparing. There is decreased sensation over the left side of her body. Which one of the following arteries is involved in this case?

A Basilar artery

B Posterior cerebral artery

C Anterior cerebral artery

D Anterior choroidal artery

E Middle cerebral artery

Ans: B

Q53) Which one of the following is the most common way by which cocaine can cause death?

A Decreased motor activity

B Hypothermia

C Decreased blood pressure

D Bradycardia

E Heart attack or stroke

Ans: E

Q54) Which one of the following statements best describes anorexia nervosa?

A Affect females in about 60% of the cases

B High enjoyment when eating

C Disturbance in the way one's body weight is experienced

D BMI is below 22

E Should start feeding them immediately with high-calorie food to prevent death

Ans: C

Q55) Which one of the following histological techniques is usually used to study myelinated axons in nerves or tracts?

A Weigert stain

B Nissl stain

C Alcian blue stain

D Golgi stain

E Hematoxylin and Eosin stains

Ans: A

Q56) A 38-year-old woman comes to the physician because of a 3-week history of involuntary movements of her extremities. Examination shows rapid, nonrepetitive jerks of her limbs and face that frequently end with the patient covering her face and yawning. She has an unsteady gait. Genetic testing shows a mutation consisting of CAG triple repeat expansion on

chromosome 4. This patient most likely has structural changes in which of the following labeled areas of the brain?

A. A

B. B

C. C

D. D

E. E

Ans: C and E were considered correct

Q57) A 45-year-old woman sees the physician because she has had morning headaches for the past 5 months. Physical examination is normal. Her brain gross appearance would have been similar to the one shown in the attached photograph. Which one of the following is the most likely diagnosis?

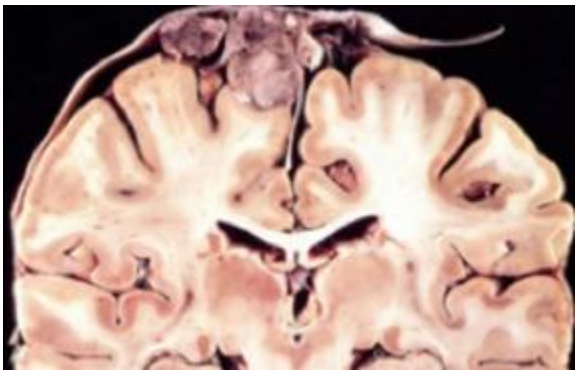

A Meningioma

B Vascular malformation

C Metastasis

D Astrocytoma

E Ependymoma

Ans: A

Q58) The attached image shows a magnified view of brain tissue from an individual with Alzheimer's disease. Which of the following structures are predominantly visible in the image?

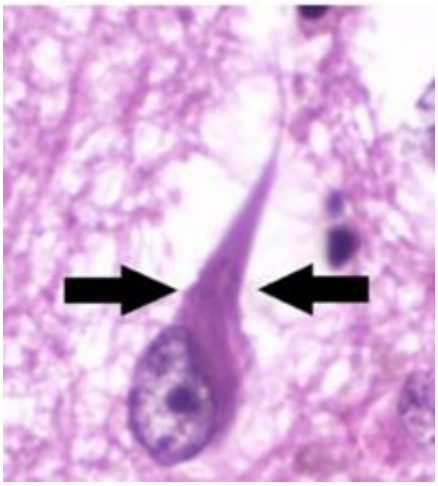

A Amyloid ß plaque

B Red neuron

C Intranuclear huntingtin protein

D Neurofibrillary tangles

E Rosenthal fibers

Ans: D

Q59) What microanatomical change is commonly associated with Alzheimer's disease and directly related to memory loss?

A Loss of dopaminergic neurons in the substantia nigra

B Lewy bodies in the neocortex

C Proliferation of astrocytes in the cerebral cortex

D Neurofibrillary tangles in the hippocampus

E Schwann cell hyperplasia

Ans: D

Q60) A 50-year-old woman has topiramate added to her therapy because she is refractory to her current antiseizure regimen. Which of the following is the correct mechanism of action of topiramate?

A Reducing current through T-type Ca2+ channels

B Activation of voltage-gated sodium channels

C Increasing current through L-type Ca2+ channels

D Antagonizing D2 dopaminergic receptors

E Enhanced GABA synaptic transmission

Ans: E

Q61) An elderly gentleman with multiple co-morbidities presents to the ER with an acute and sudden right sided weakness and aphasia. His CT image (attached) shows an important early sign. What is this sign?

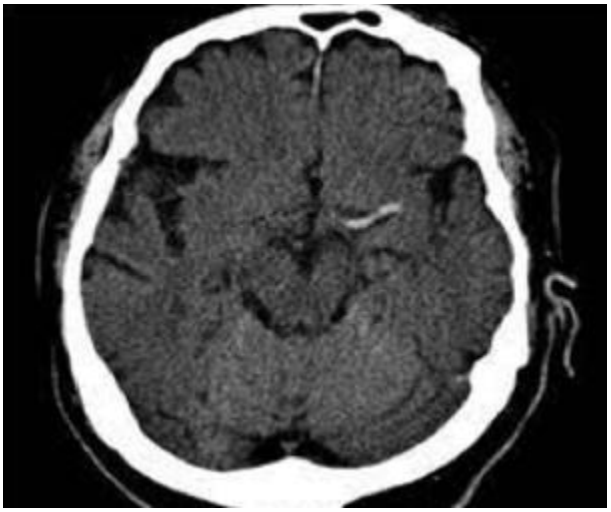

A Hypodensity sign

B Loss of grey-white differentiation sign

C Hyperdense MCA sign

D Cortical Ribboning sign

E Disappearing Basal Ganglia sign

Ans: C

Q62) A patient came to neurology clinic with a brain stroke. On neurological examination the patient was asked to open and close his right fist alternately and rapidly. This alternate movement became discoordinated. Which one of the following areas of the brain is affected by this stroke?

A Posterior spinocerebellar tract

B Right cerebellar hemisphere

C Vermis of the cerebellum

D Inferior cerebellar peduncle

Ans: B

Q63) A 55-year-old woman develops progressive difficulty lifting objects and climbing stairs. Over the next year, she experiences increasing weakness in her legs and arms, slurred speech, and difficulty swallowing. Neurological examination reveals muscle wasting, fasciculations, hyperreflexia, and bulbar symptoms. Which of the following is the most likely diagnosis?

A Amyotrophic Lateral Sclerosis

B Stroke

C Guillain-Barre syndrome

D Multiple sclerosis

E Myasthenia Gravis

Ans: D

Q64) For the treatment of insomnia in a patient, which medication is preferred due to its broader safety profile and lower risk of dependence?

A Zolpidem

B Thiopental

C Midazolam

D Flurazepam

E Clonazepam

Ans: A

Q65) A 60-year-old after a stroke presented with right sided spastic paralysis and left medial strabismus. Which one of the following is the site of the lesion?

A Left crus cerebri

B Right crus cerebri

C Right basilar pons

D Left basilar pons

E Right internal Capsule

Ans: D

Q66) An elderly patient hit his head to a wall. An urgent CT of the brain is shown. What is the most likely diagnosis?

A Ischemic Stroke

B Calcification

C Hyperintense Lesions for further investigation

D Intra-ventricular Hemorrhage

E Intracerebral Hemorrhage

Ans: E

Q67) In the mouse model of multiple sclerosis (MS), T cells specific for which antigen are infused into the animal to cause the characteristic pathology of MS?

A FcRn

B L-selectin

C Myelin-basic protein

D B-integrins

E MadCAM-1

Ans: C

Q68) A demanding 25-year-old woman begins psychotherapy stating that she is both desperate and bored. She reports that for the past 5 or 6 years she has experienced periodic anxiety and depression and has made several suicidal gestures. She also reports a variety of impulsive and self-defeating behaviors and sexual promiscuity. She wonders about her sexual orientation. She has abruptly terminated two previous attempts at psychotherapy due to conflict with therapist. Which one of the following is the most likely diagnosis?

A Schizoid personality disorder

B Impulse control disorder

C Histrionic personality disorder

D Antisocial personality disorder

E Borderline personality disorder

Ans: E

Q69) Which one of the following nuclei is responsible for correction of fine skilled movements of the distal limbs?

A Nucleus Fastigial

B Nucleus Globose

C Nucleus Dentate

D Nucleus Gracilis

E Nucleus Emboliform

Ans: C

Q70) A radiographic image of patient's brain is shown. The radiologist has informed you that there are small scattered perpendicular looking white matter changes. What do these changes signify?

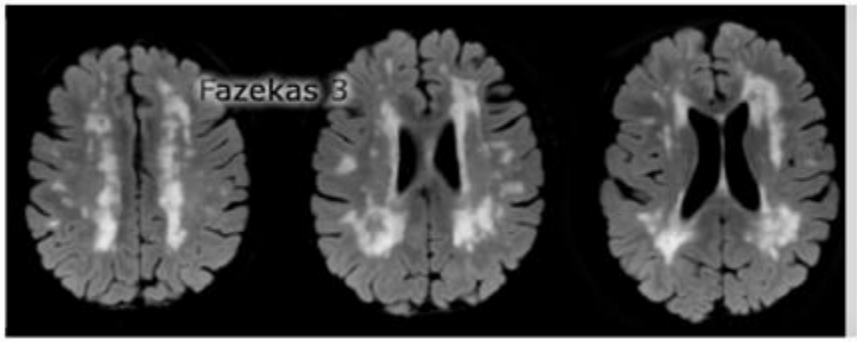

A. Migraine Lesions

B. Chronic Microangiopathic changes

C. Demyelinating Lesions

D. Infection

Ans: B

Q71) A 25-year-old male patient with a history of schizophrenia presents with positive symptoms such as hallucinations and delusions. He has not responded well to first-line antipsychotic treatment. Which of the following atypical antipsychotic medications can be considered as a second-line option?

A. Chlorpromazine
B. Haloperidol
C. Aripiprazole
D. Risperidone

Ans: D

Q72) "Blackout" in people who abuse alcohol is the result of which one of the following?

A. Not paying attention to details during intoxication
B. Dopamine increase
C. Decrease in glutamate
D. Damage to the hippocampus

Ans: D

Q73) A 30 year old female with a pattern of being seductive, rapid shift in emotions, being easily influenced by others, and always wanting to be the center of attention. Which one of the following is the most likely disorder?

A. Borderline personality disorder
B. Schizotypal personality disorder
C. Histrionic personality disorder
D. Narcissistic personality disorder
E. Antisocial personality disorder

Ans: C

Q74) Inhibitory enkephalinergic interneurons in the dorsal horn of the spinal cord activate opiate receptors in the pre- and post-synaptic membranes in the synapse between first and second order sensory neurons and can stop pain transitions in case of the stress-induced analgesia. Which of the following is the result of activation opiate receptors in the presynaptic membrane?

A. Closing NMDA channels
B. Closing calcium-dependent inwardly-rectifying K+ channels
C. Closing N-type voltage-operated Ca++ channels
D. Opening calcium-dependent inwardly-rectifying K+ channels
E. Opening N-type voltage-operated Ca++ channels

Ans: C

Q75) A female experienced sudden loss of vision after reading a romantic message from her husband to another lady. This is an example of which one of the following conditions?

A. Somatic symptom disorder
B. Conversion disorder
C. Illness anxiety disorder
D. Histrionic personality disorder
E. Adjustment disorder

Ans: B

Q76) A 65-year-old male patient with Parkinson's disease presents with worsening motor symptoms. He has been taking levodopa/carbidopa combination therapy for the past two years. Which of the following medications can be added to his current regimen to provide additional symptomatic relief?

A. Apomorphine
B. Benztropine
C. Bromocriptine
D. Pramipexole

Ans: D

Q77) Which part of the hippocampal formation is very susceptible to anoxia such as that caused by cardiac arrest?

A. Entorhinal cortex (ERC)
B. CA1 (Sommer's sector)
C. CA3 and Schaffer collaterals
D. Subiculum
E. Dentate gyrus

Ans: B

Q78) If there is a fracture of L4 vertebra, which one of the following are at risk of damage?

A. Sacral nerve
B. Lumbar part of spinal cord
C. Cauda equina
D. Femoral nerve
E. Sacral part of spinal cord

Ans: C

Q79) Alzheimer's disease is characterized by the accumulation of abnormal protein aggregates in the brain. Which one of the following protein aggregates is considered a hallmark of Alzheimer's disease pathology?

A. Lewy bodies
B. Amyloid plaques
C. TDP-43 inclusions.
D. Alpha-synuclein aggregates
E. Tau tangles

Ans: B

Q80) A 68-year-old woman was admitted to ER after initially complaining of dizziness. The patient indicated that she could not move her left arm or leg, and her speech was slurred. The tongue was directed to the left side when the patient was asked to protrude it, and the patient's jaw also drooped to the left side. Sensory functions on each side of the body appeared normal, and motor functions on the right side. Which of the following blood vessels is most likely compromised?

A. Lenticulostriate branches of the left MCA
B. Thalamoperforating branches of right PCA
C. Artery of Percheron
D. Thalamoperforating branches of left PCA
E. Lenticulostriate branches of the right MCA

Ans: A

Q81) Which of the following antiepileptics has a potent effect on the T-type calcium channels in thalamic neurons?

A. Carbamazepine
B. Ethosuximide
C. Phenytoin
D. Lamotrigine

Ans: B

Q82) A 75-year-old woman died due to a respiratory tract infection. She was a known case of a motor disorder for the last many years. On autopsy, one of her basal ganglia was found depigmented as shown in the attached figure. Which one of the following diseases she was suffering from?

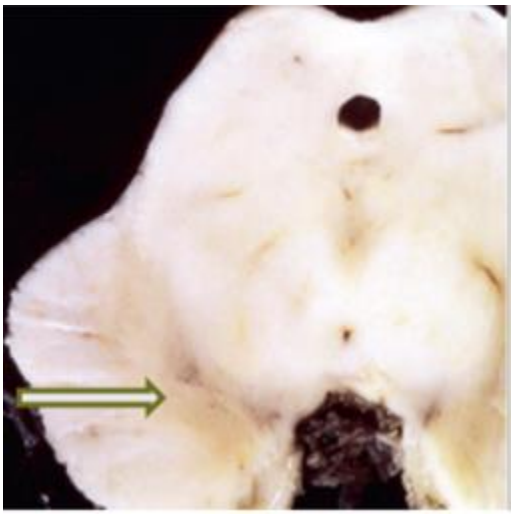

A. Multiple sclerosis
B. Alzheimer disease
C. Wallerian degeneration
D. Huntington disease
E. Parkinson disease

Ans: E

Q83) A 15-year-old girl visited the psychiatrist with her mom, complaining of loss of appetite and a severely low body mass index (BMI). What would be the best treatment for her case?

A. Escitalopram

B. Mirtazapine
C. Venlafaxine
D. Fluoxetine
E. Amitriptyline

Ans: D

Q84) A long case about a diabetic 50 year old with fever, What is the agent of infection?

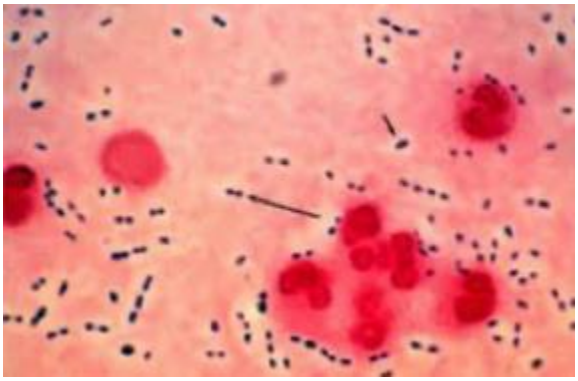

A. Staphylococcus aureus
B. Streptococcus agalactiae
C. Staphylococcus epidermidis
D. Streptococcus pneumoniae
E. Streptococcus pyogenes

Ans: D

Q85) A 23-year-old male brought by family to the hospital with a history of gradual onset of suspiciousness, paranoia, isolation, violent outbursts, and lack of interest in his studies. These symptoms have been going on for over 6 months. He denied any drug use. Mental status exam revealed a sad mood, with flat affect, thought broadcast, and impaired judgment. He is most likely suffering from which one of the following conditions?

A. Schizophrenia
B. Schizoaffective disorder
C. Delusional disorder
D. Major depression with psychotic features
E. Bipolar disorder with psychotic features

Ans: A

Q86) A patient, known case of prostate cancer with bone metastasis, was admitted for pain control. He was placed on morphine for pain relief, however, the pain relief was not adequate, so the resident on duty replaced morphine with pentazocine. After receiving pentazocine, patient's pain became worse and he started crying. This worsening of pain after getting pentazocine is mediated through which of the following effects/mechanisms?

A. Agonism at kappa receptors
B. Agonism at delta receptors
C. Agonism at mu receptors
D. Antagonism at mu receptors
E. Antagonism at kappa receptors

Ans: D

Q87) A 17-year-old boy presents with acute onset of headache, fever, and stiff neck. The following day, his symptoms worsened, and a petechial rash developed over his extremities. Cerebrospinal fluid reveals Gram-negative diplococci, with a predominance of polymorphonuclear cells. What is the pathogen of infection?

A. Haemophiles influenzae type A
B. Neisseria meningitidis
C. Haemophiles influenzae type B
D. Streptococcus pneumoniae
E. Escherichia coli

Ans: B

Q88) McDonalds Criteria for Multiple Sclerosis lesions states that they should show dissemination in time and space. This can be assessed radiologically by which of the following parameters?

A. Having an MRI Brain image with 1 non-enhancing lesion only
B. Having an MRI Brain image with 1 enhancing lesion only
C. Having an MRI Brain image with 2 lesions. Both equally enhancing
D. Having an MRI Brain image with 2 lesions. Both equally non-enhancing
E. Having an MRI Brain image with 2 lesions. One is enhancing and the other is not

Ans: E

Q89) A 70-year-old female patient with Parkinson's disease is experiencing dyskinesias as a side effect of levodopa therapy. Which one of the following medications can help reduce dyskinesias by inhibiting a minor metabolizing pathway of levodopa?

A. Safinamide
B. Rotigotine
C. Tolcapone
D. Rasagiline

Ans: C

Q90) Dirty unkempt appearance suggests which one of the following condition(s)?

A. Alcoholism and drug addiction
B. Dementia
C. Schizophrenia
D. Homelessness
E. All of the above

Ans: E

Q91) A 27-year-old woman with a history of seizures was talking with her friends when she suddenly experienced the onset of strong contraction of her left and right limb muscles that lasted about 30 seconds which was accompanied by a grunting sound and momentary loss of consciousness causing her to collapse; this was immediately followed by jerking of her limbs that lasted for about 2 minutes. This description is consistent with which of the following?

A. Simple partial seizure
B. Tonic-colonic seizure
C. Atonic seizure
D. Complex partial seizure

Ans: B

Q92) A 38-year-old woman reports to her physician jerky movements of her limbs and trunk for the past few months.Examination shows choreatic movements. Genetic testing reveals a mutation consisting of expansion of CAG repeats on chromosome 4. Which one of the following is the most likely change seen on brain MRI?

A. Demyelination of cortical white matter
B. Atrophy of the striatum
C. Depigmentation of substantia nigra

Ans: B

Q93) A 59-year-old woman comes to the physician because of progressively worsening involuntary movements in her left hand for the past 6 months. She is oriented to time, place, and person. Examination shows resting tremors in both hands. There is increased resistance to passive flexion and extension in the limbs. Active movements are very slow, and she walks with a shuffling gait. Which of the following is the most likely underlying cause of this patient's symptoms?

A. Loss of myelin sheath and oligodendrocytes
B. Aggregates of Tau protein in neurons with gliosis
C. Degeneration of upper and lower motor neurons
D. Aggregates of a-synuclein protein in neurons

Ans: D

Q94) Which of the following factors is known to increase the risk of neural tube defects?

A. Zinc deficiency
B. Smoking during pregnancy
C. Sufficient folic acid intake
D. Hyaluronate deficiency
E. Being underweight during pregnancy

Ans: D

Q95) A 75-year-old woman experiences increasing forgetfulness, difficulty finding words, and confusion over the past year. She becomes easily lost in familiar places and struggles to follow conversations. Which of the following is the most likely diagnosis?

A. Alzheimer disease
B. Lewy body dementia
C. Vascular dementia
D. Parkinson disease
E. Huntington Disease

Ans: A

Q96) A oldman presented with tremors, rigidity, and bradykinesia. His symptoms have been worsening over the past few months. Which of the following is the most likely pathological finding in his brain?

A. Diffuse atrophy of the cerebral cortex
B. Lewy bodies in the substantia nigra
C. Huntington's disease protein aggregates in the striatum
D. Beta-amyloid plaques in the hippocampus

Ans: B

Q97) A patient with severe vitamin B12 deficiency and degenerative changes in the spinal cord will present with which one of the following neurological signs?

A. Decreased sense of pain in the contralateral leg
B. Loss of pain in the ipsilateral leg
C. Decreased vibratory sense in the ipsilateral arm
D. Decreased sense of temperature in the ipsilateral arm
E. Decreased strength of the contralateral leg

Ans: C

Q98) A 45-year-old patient with demyelinating disease effecting the left lateral medulla came to the neurology clinic. He will present with which one of the following clinical features?

A. Loss of pain sensation from the left half of the body
B. Loss of pain sensation from the left side of the face

C. Loss of discriminatory touch from the left half of the body
D. Spastic paralysis involving the right half of the body
E. Loss of vibration from the right half of the body

Ans: B

Q99) An 89-year-old male developed progressively worsening memory loss, impaired language function, and altered social skills over the last five years. His consciousness level is not altered. Which brain region will show the most significant neurofibrillary tangles in this patient?

A. Striatum
B. Cerebellum
C. Thalamus
D. Globus pallidus
E. Hippocampus

Ans: E

Q100) Which one of the following is an important clinical indication for varenicline?

A. Depression
B. Parkinson's disease
C. Bipolar disorder
D. Smoking cessation

Ans: D

Q101) A 37-year-old woman experiences a sudden episode of vision loss in one eye followed by slurred speech and numbness in her right arm. An MRI scan shows lesions in the optic nerve and brainstem. She undergoes a lumbar puncture revealing elevated IgG levels. Which of the following is the most likely diagnosis?

A. Migraine
B. Multiple sclerosis
C. Guillain-Barre syndrome
D. Stroke

Ans: B

Q102) A 64-year-old man comes to the emergency department due to left lower extremity weakness. Left lower extremity examination shows motor power is 0/5, deep tendon reflexes are 3+, and Babinski is sign is present. Right lower extremity examination is normal. An abnormality in which of the following structures is the most likely cause of this patient's symptoms?

A. Anterior spinal artery of the lumbosacral region
B. Lumbosacral spinal neuroforamina
C. Right middle cerebral artery
D. Left posterior inferior cerebellar artery
E. Right anterior cerebral artery

Ans: E

Q103) A 30-year-old male, with no known co-morbidities, presents to hospital emergency with two days history of increasing headache, fever and neck stiffness. He also complains of photophobia. On examination, he looks in distress, has neck rigidity and a temperature of 39 degrees Celsius. Which of the following combination of antimicrobial drugs is the most appropriate empiric choice to treat this patient's condition?

A. Clindamycin + Vancomycin
B. Amphotericin B + Ceftazidime
C. Ceftriaxone + Vancomycin
D. Vancomycin + Rifampicin
E. Nafcillin + Acyclovir

Ans: C

Q104) If the right globus pallidus internus of the lentiform nucleus (basal ganglia) is degenerating, the neurons of which of the following thalamic nuclei will show trans neuronal degeneration because of its connection with the globus pallidus?

A. Right ventral posteromedial
B. Left ventral lateral
C. Intralaminar
D. Right ventral lateral
E. Left ventral posterolateral

Ans: D (Appealed)

اللهم إني أستودعك ما قرأت وما حفظت، وما تعلمت، فرده اليّ عند حاجتي إليه